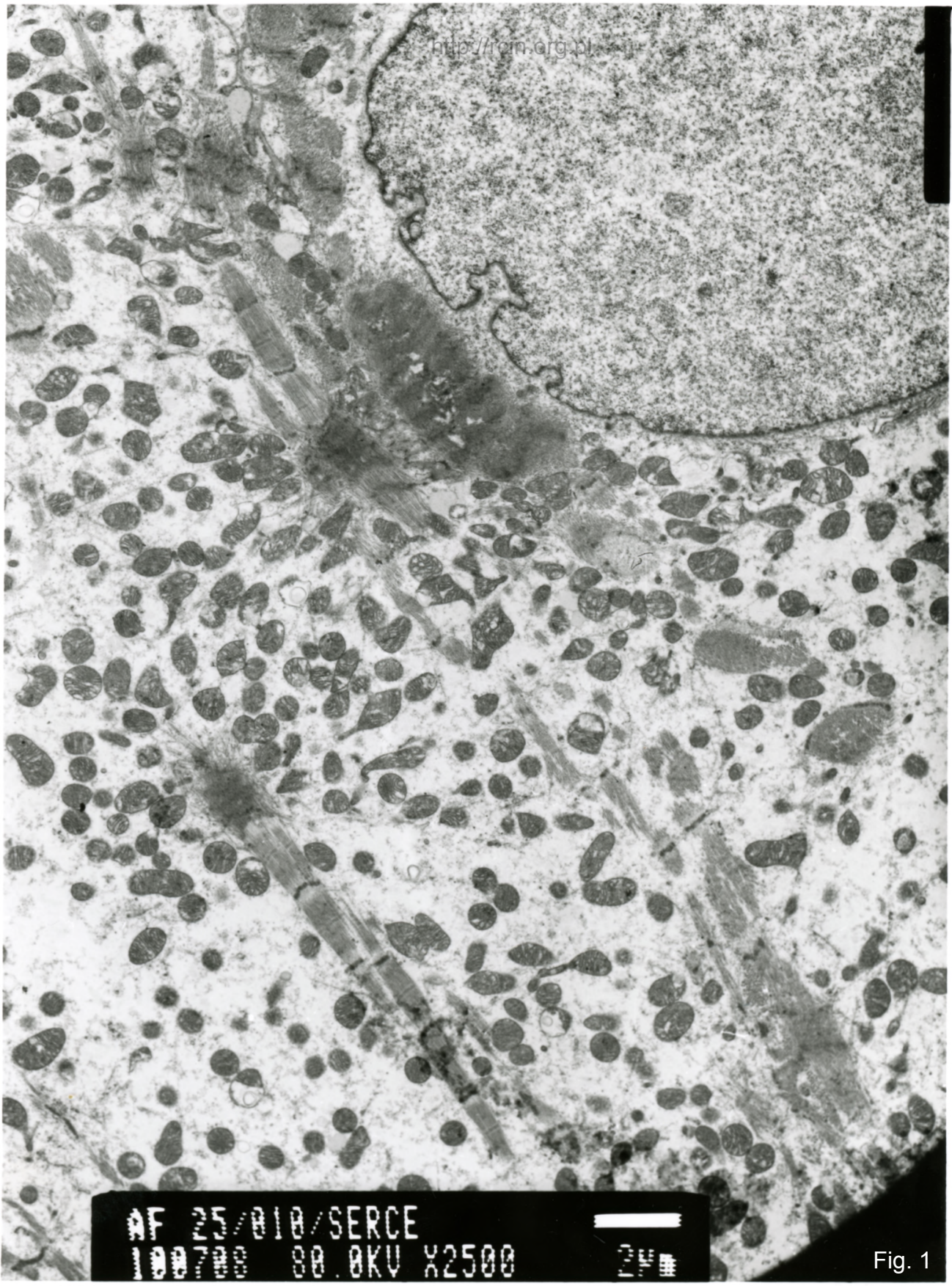



AF 25/010/SERCE  
100700 80.0KV X2500



Fig. 1

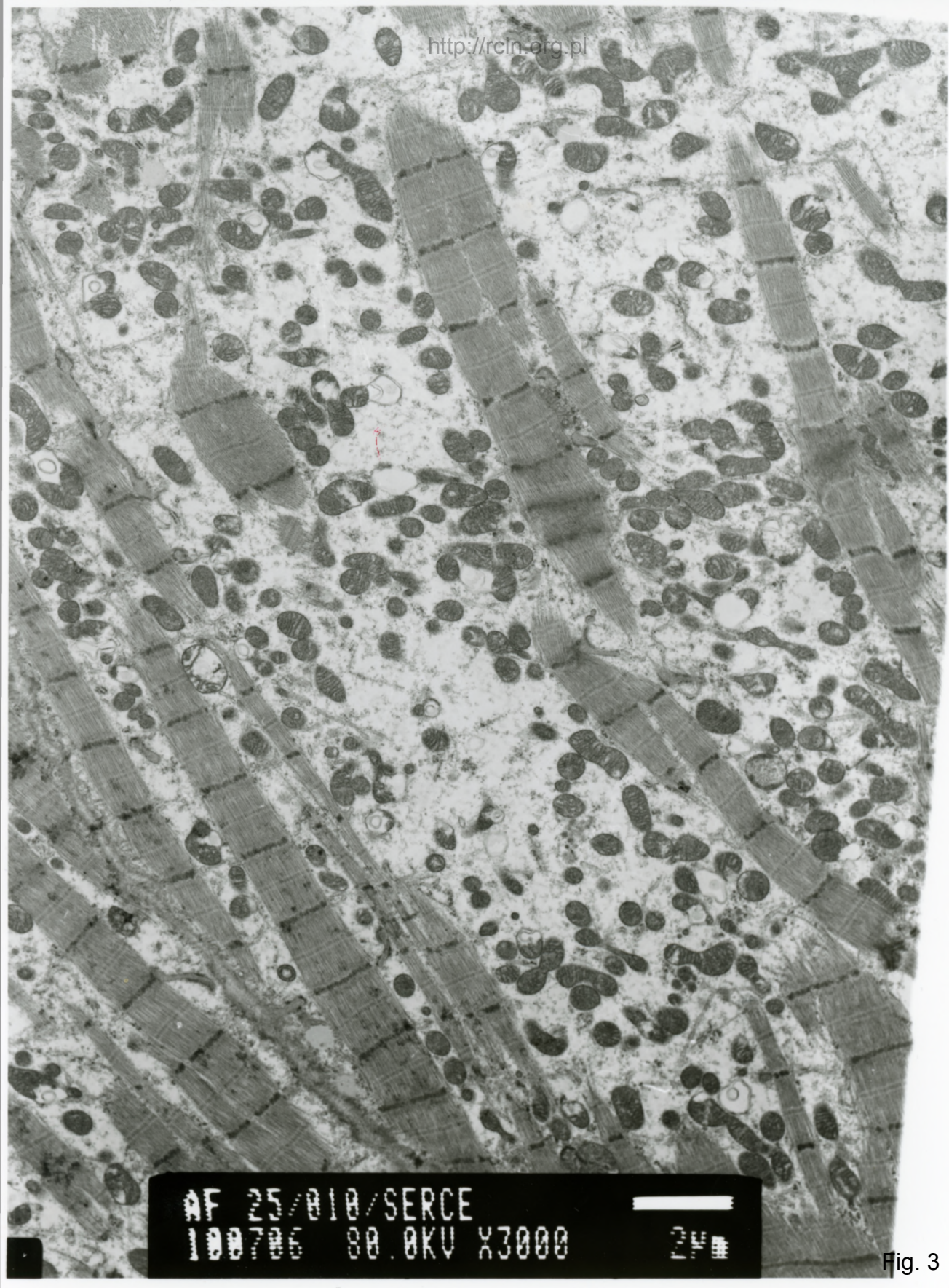


AF 25/010/SERCE  
100707 80.0KV X3000



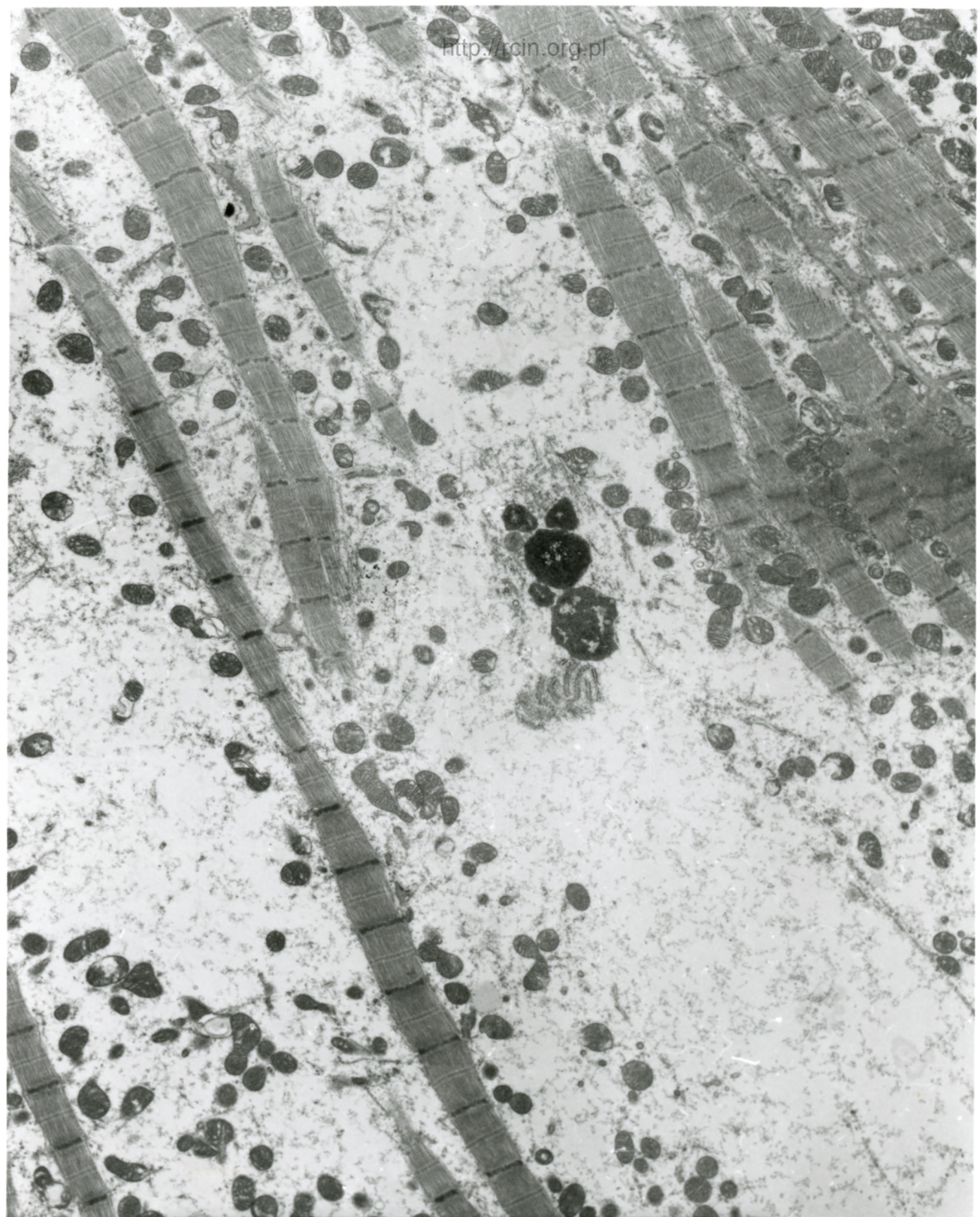
2µm

Fig. 2



AF 25/010/SERCE  
100706 80.0KV X3000 24

Fig. 3



AF 25/010/SERCE  
100700 80.0KV X2500




Fig. 4

25/10

#### Uszkodzenie mięśnia sercowego nieznanego pochodzenia

W ocenie ultrastrukturalnej widoczne zaburzenia w przebiegu miofilamentów i dezorganizacja sarkomerów. W sarkoplazmie obecne są liczne zmienione morfologicznie mitochondria (Fig. 1,2,3,4).

#### Heart muscle injury of unknown etiology

Ultrastructural evaluation revealed disrupture in the course of myofilaments and sarcomeres disorganization. Numerous morphologically altered mitochondria were present in the sarcoplasm (Figs. 1,2,3,4).