Fig. 1

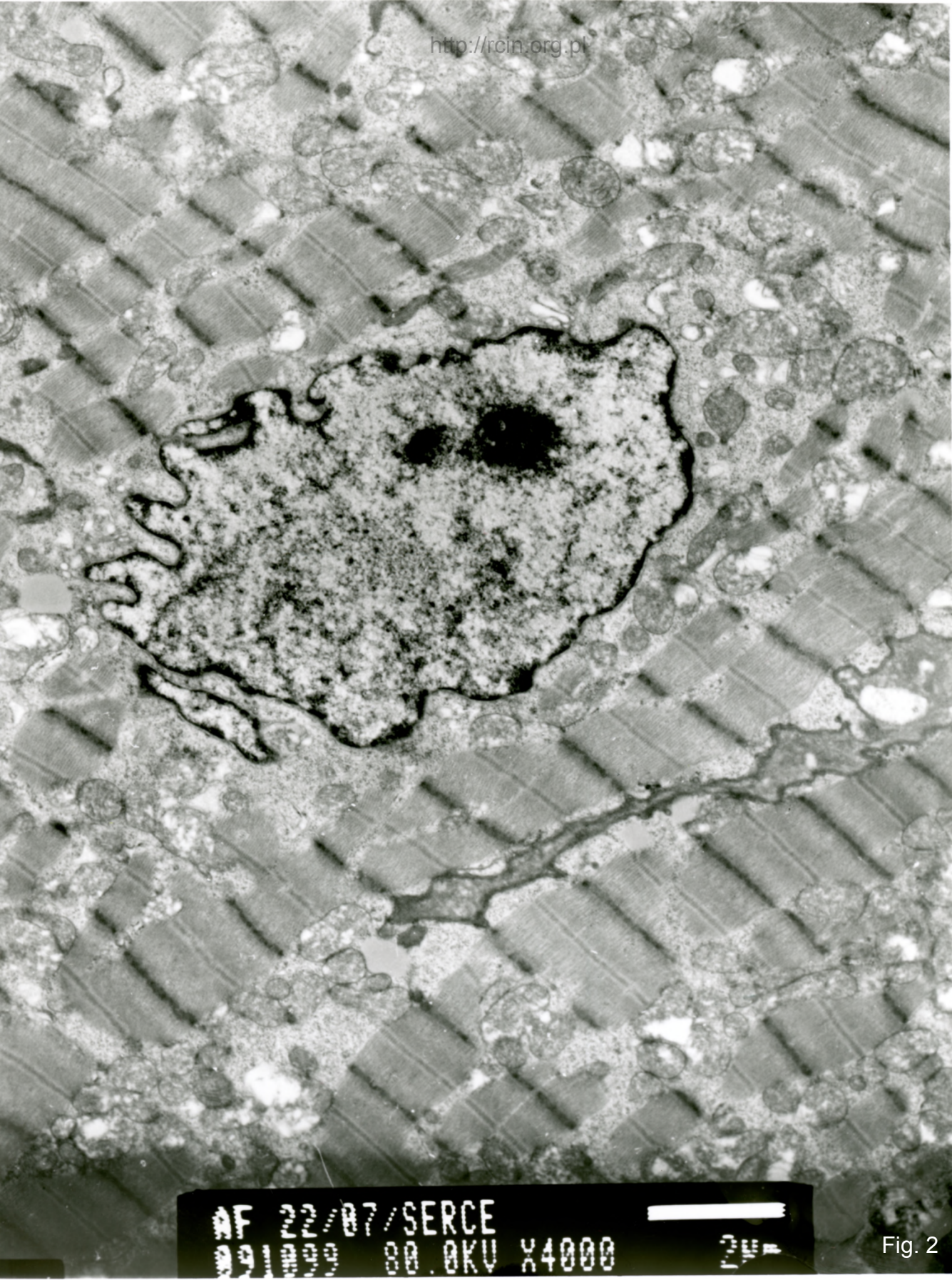

Fig. 2

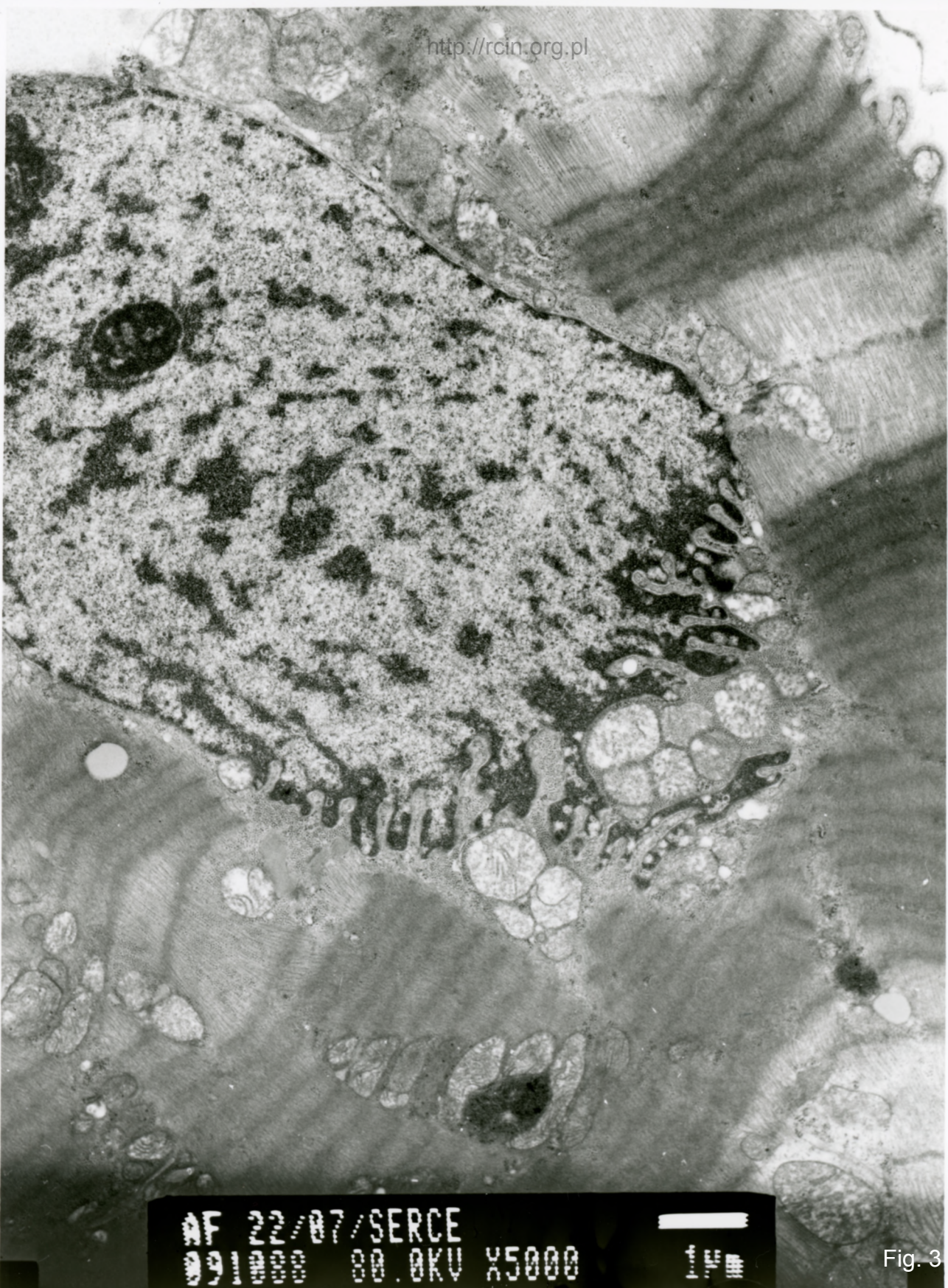

Fig. 3



Fig. 4

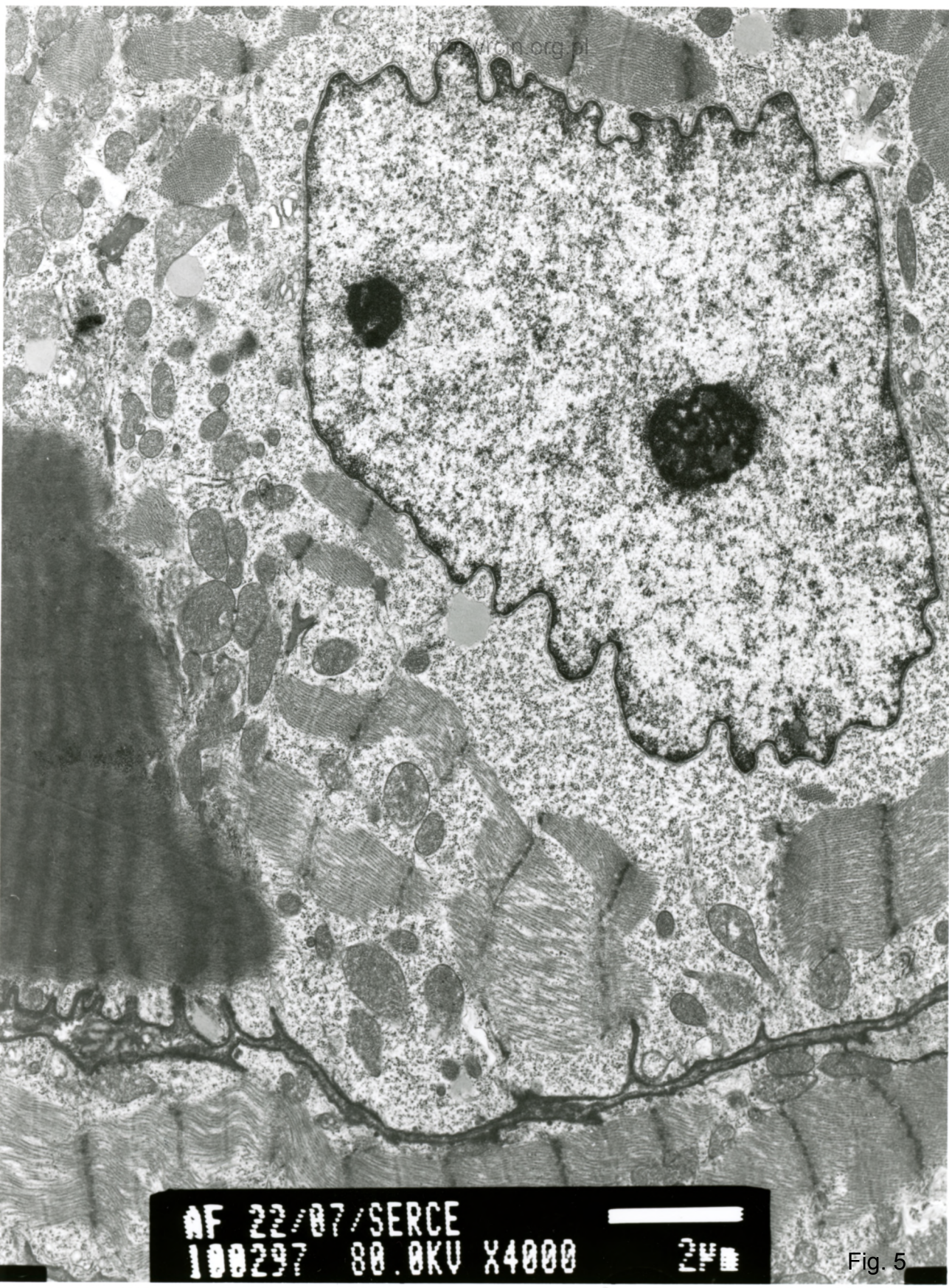

Fig. 5

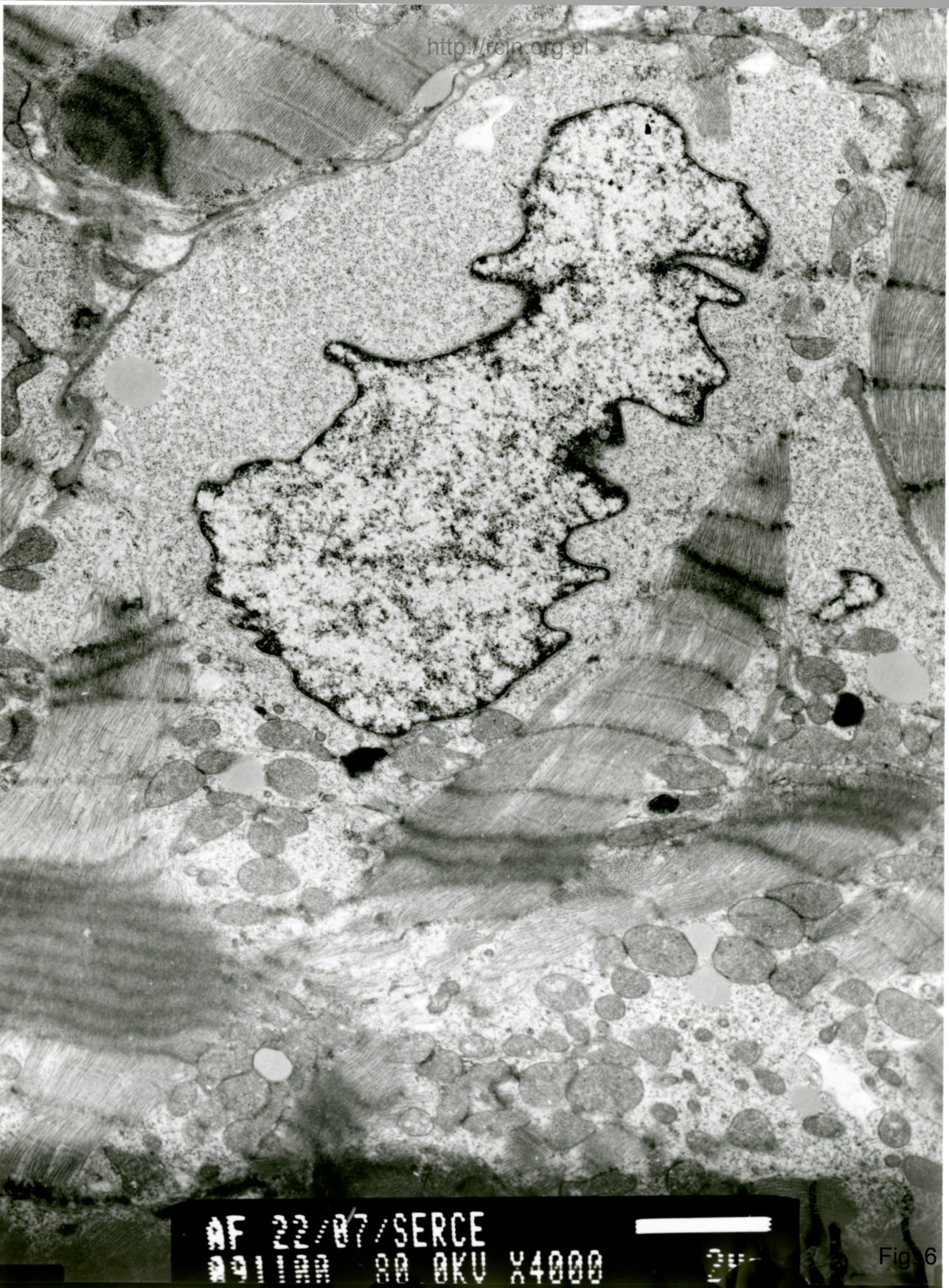

Fig. 6

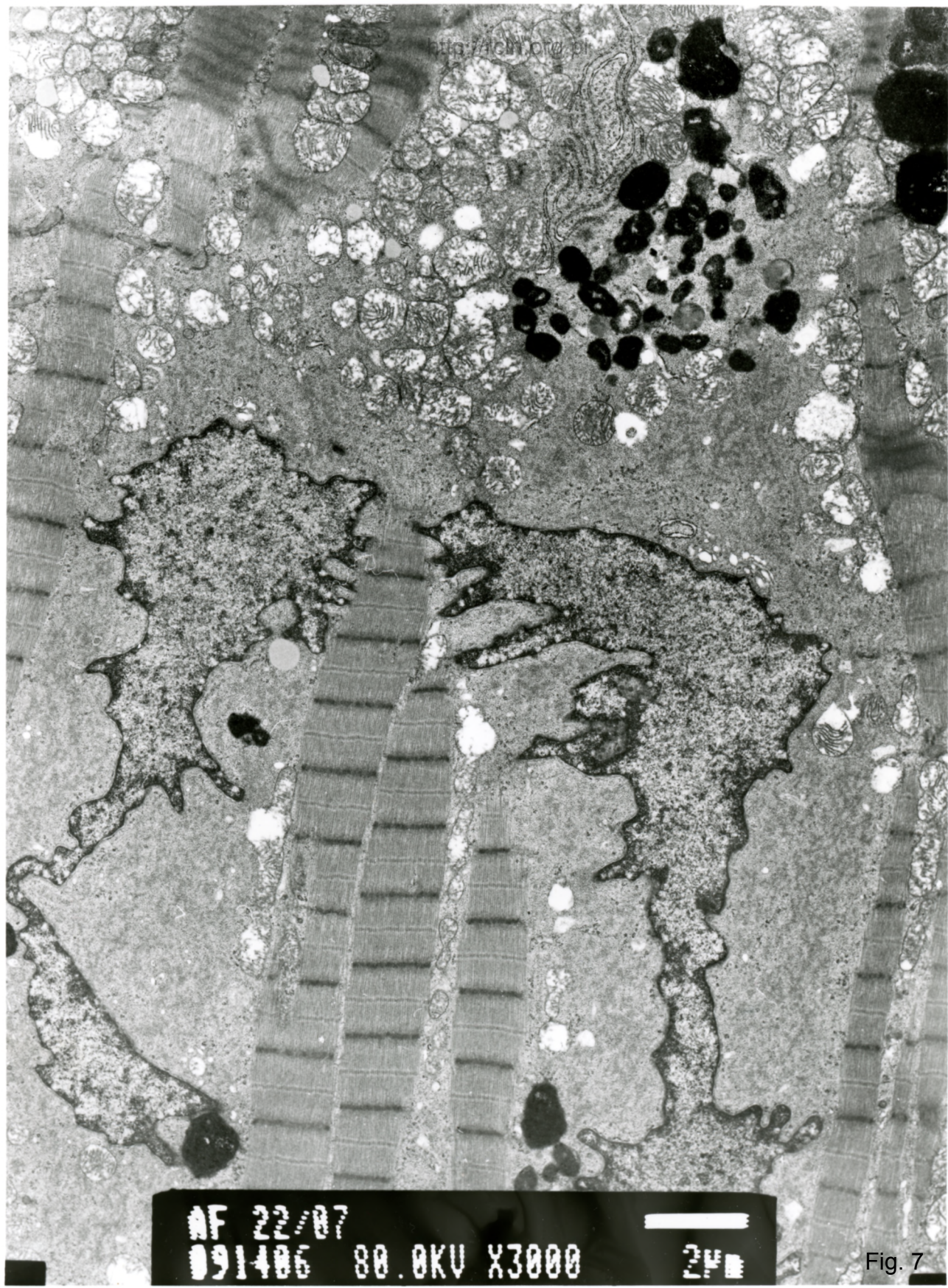

Fig. 7

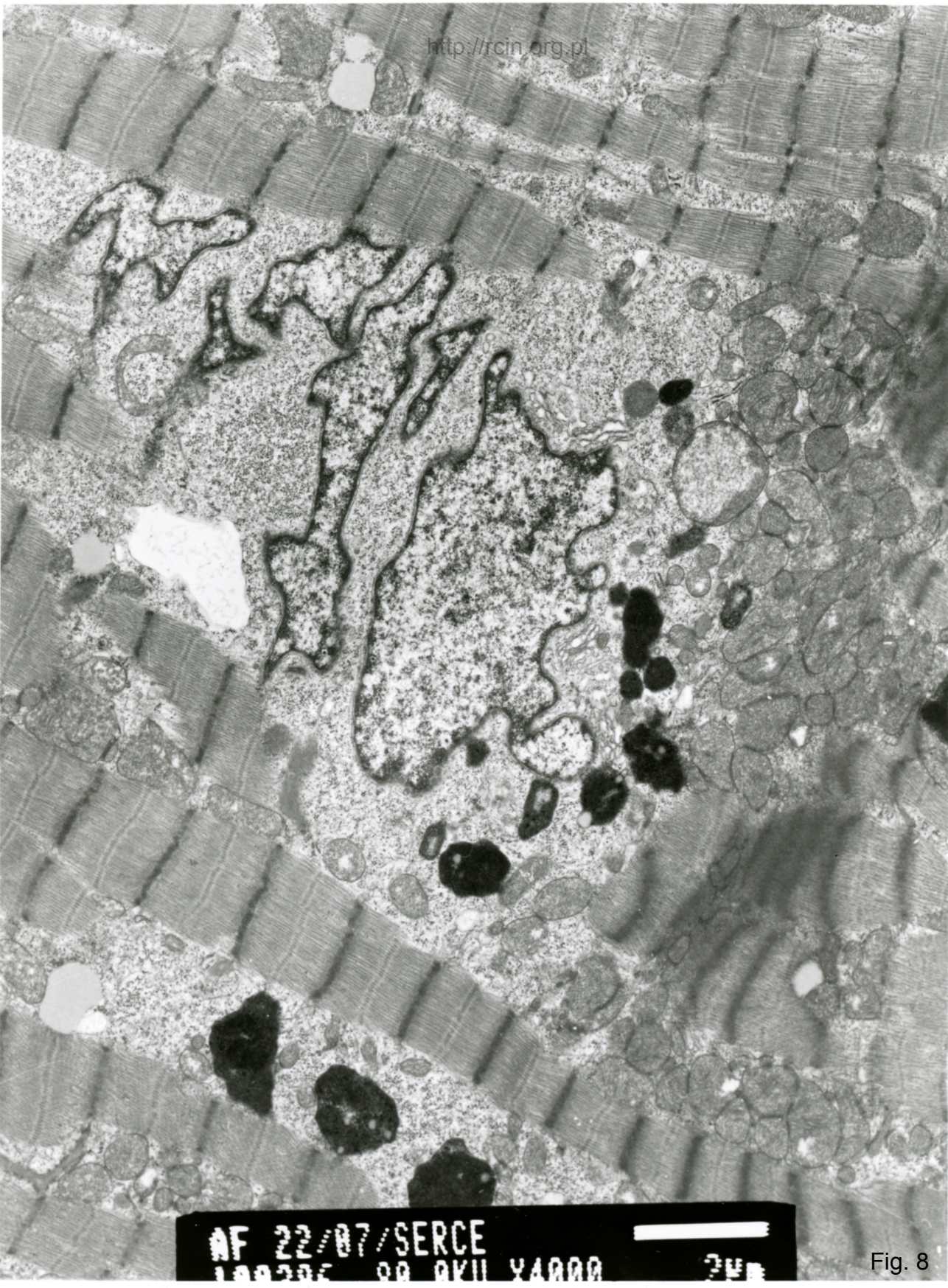

Fig. 8

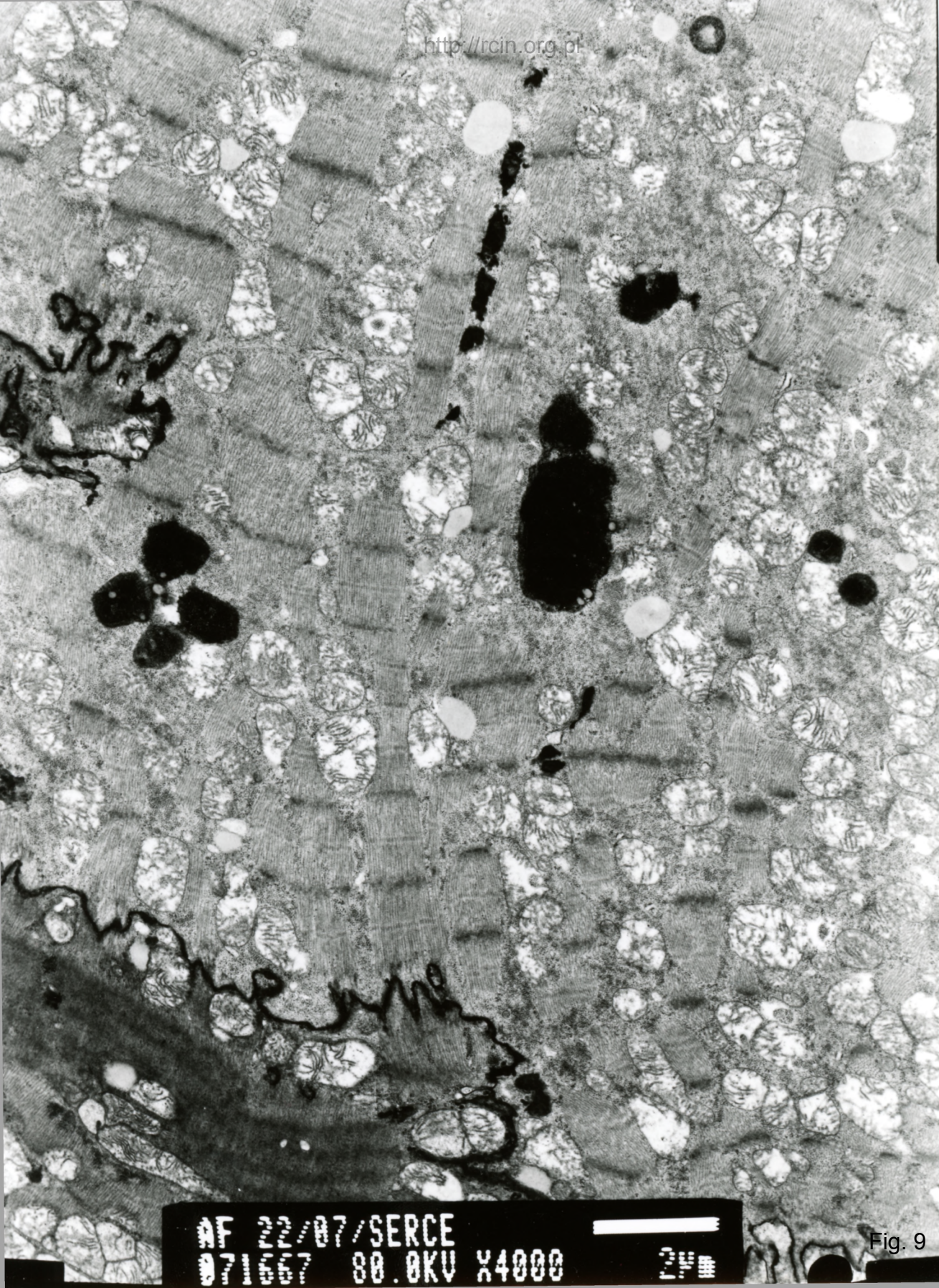

Fig. 9

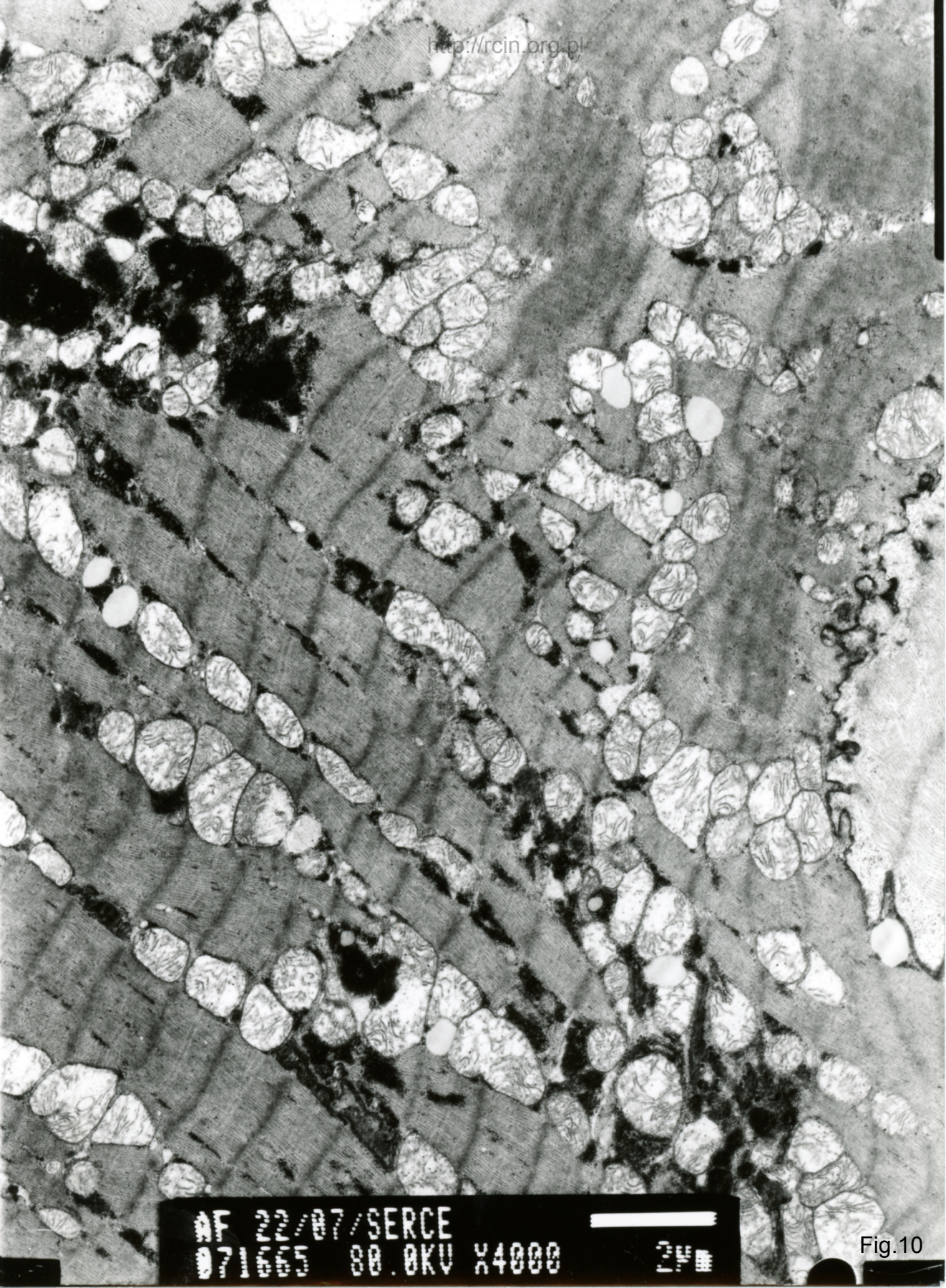

Fig.10

Fig.11

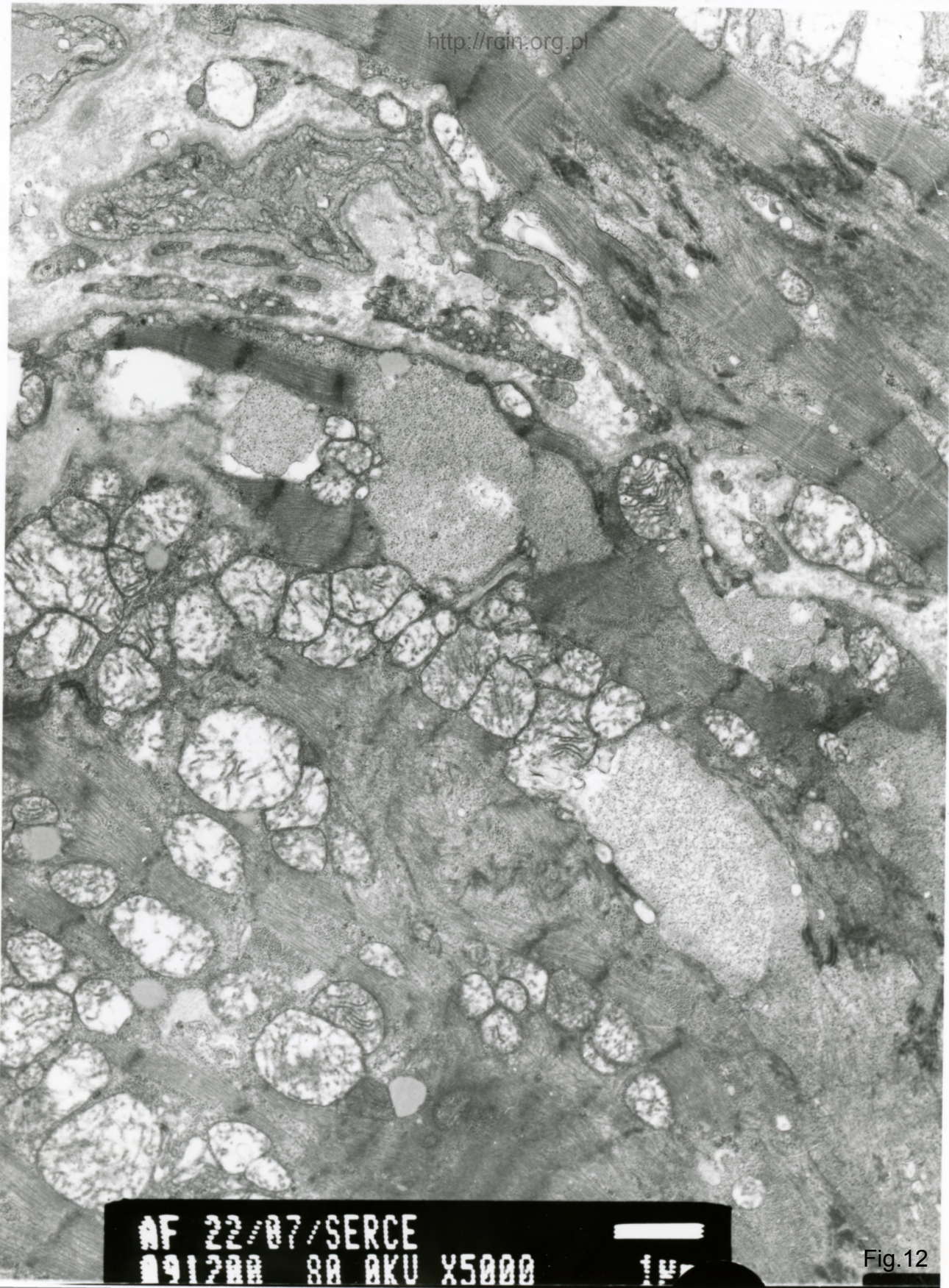

Fig.12

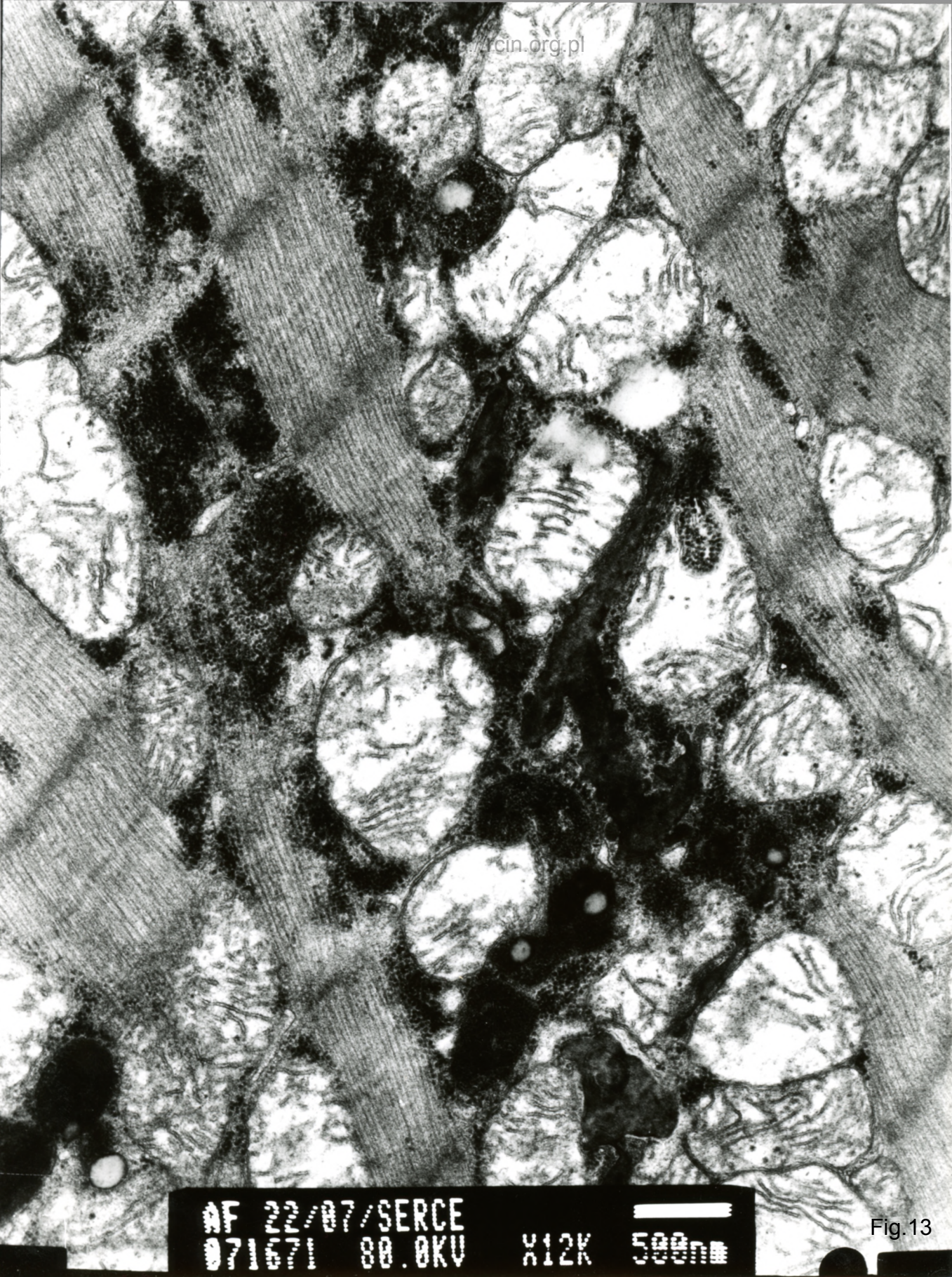

Fig.13

Fig.14

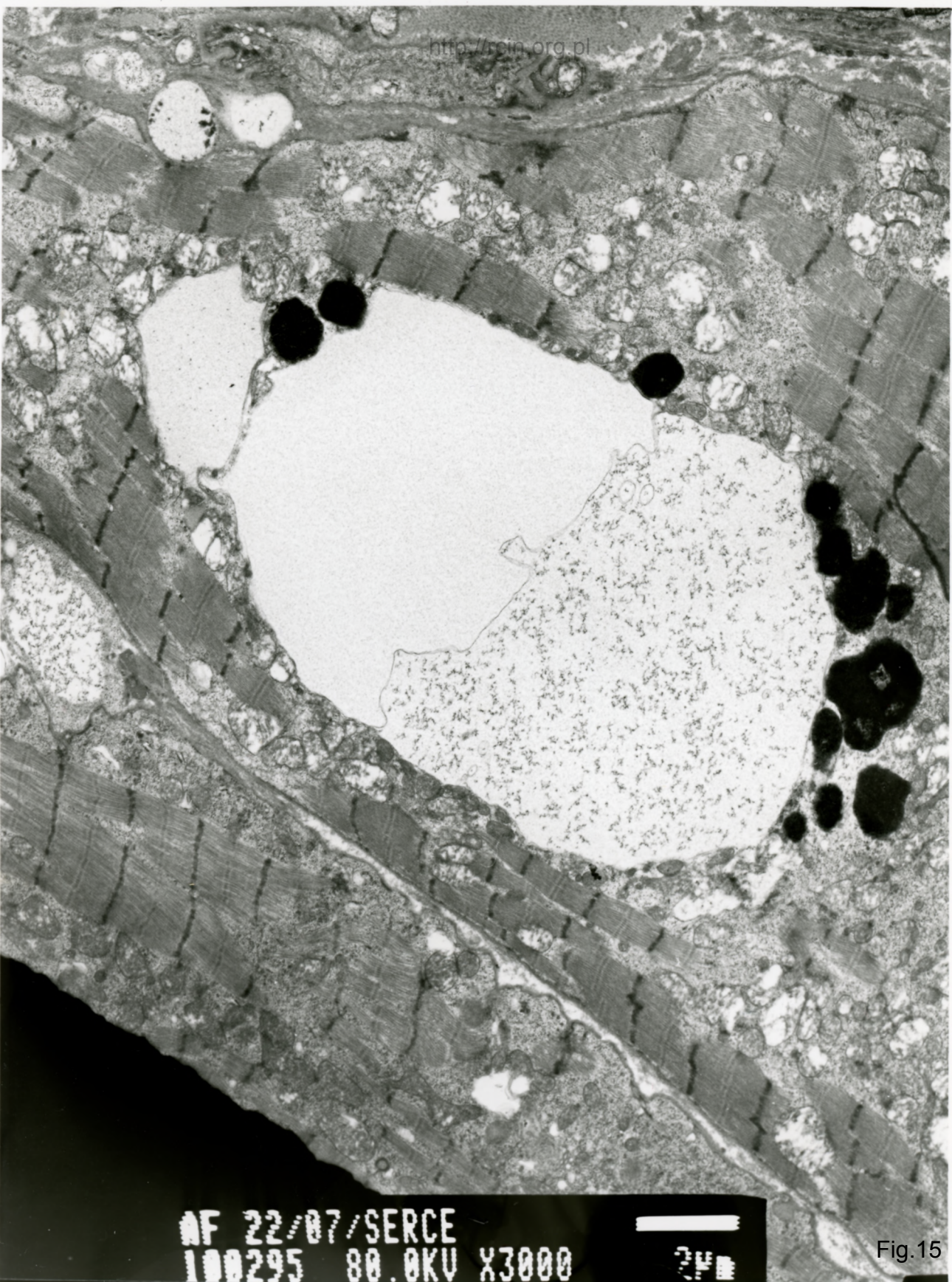

Fig.15

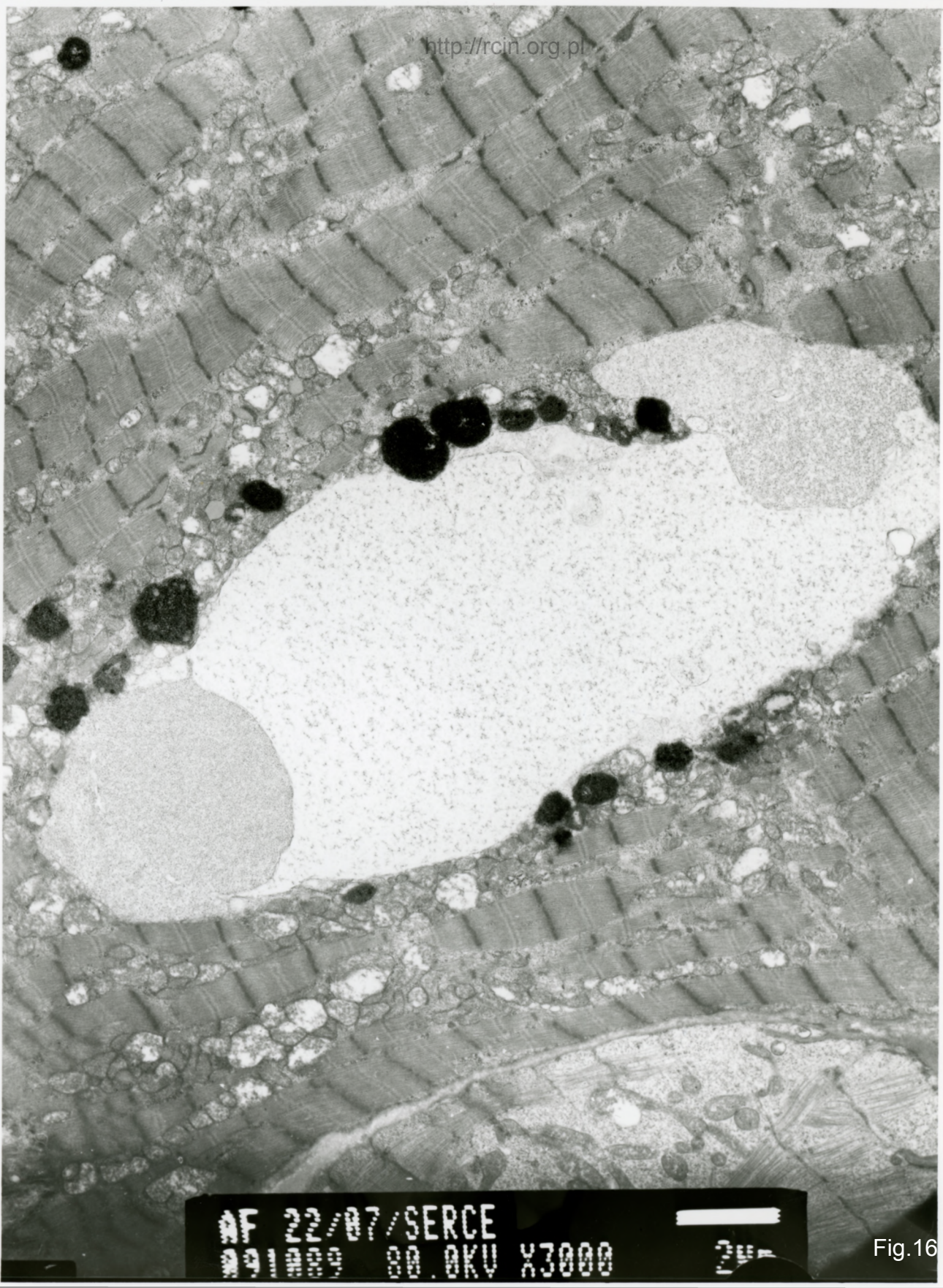

Fig.16

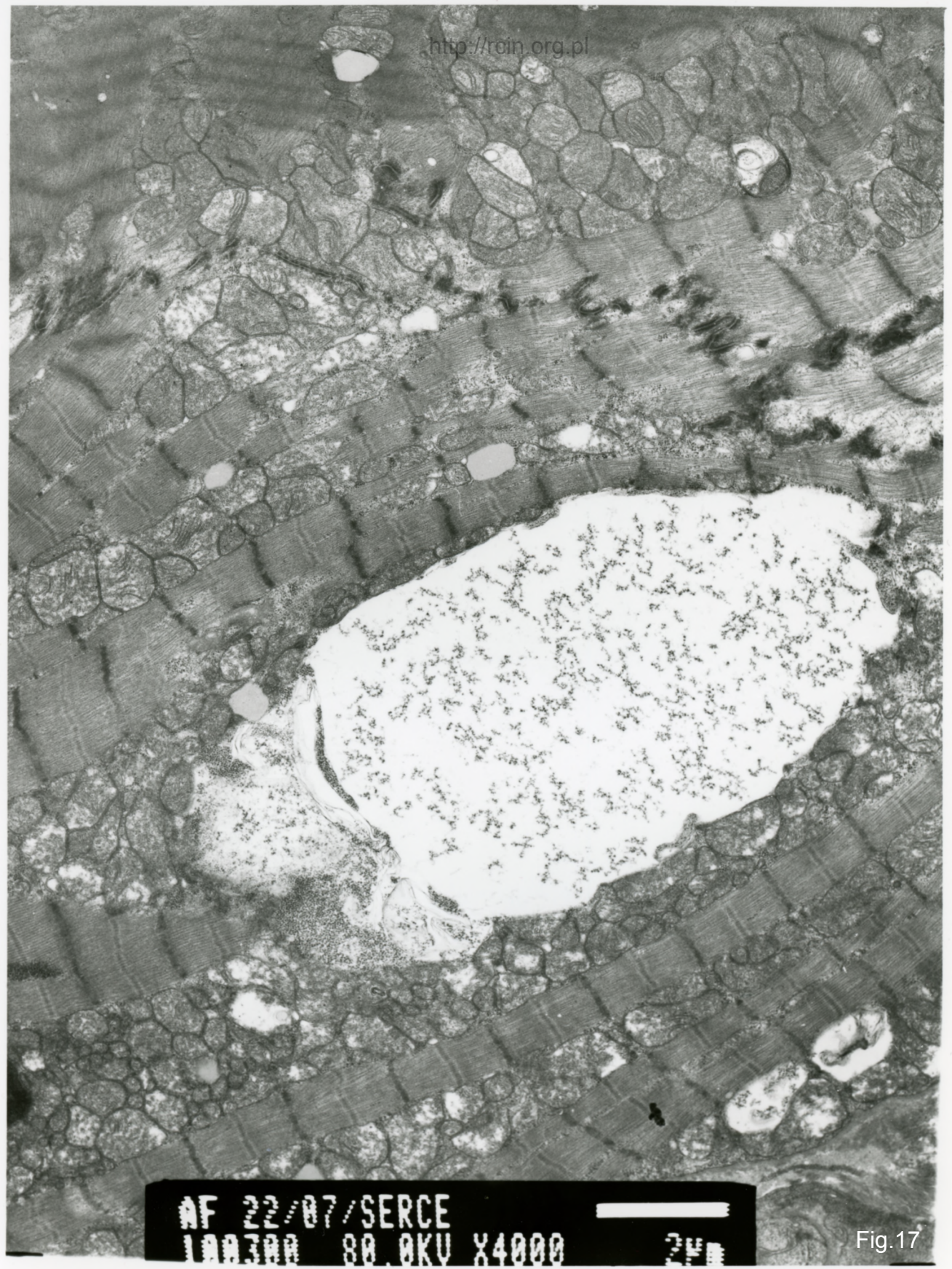

Fig.17

Fig.18

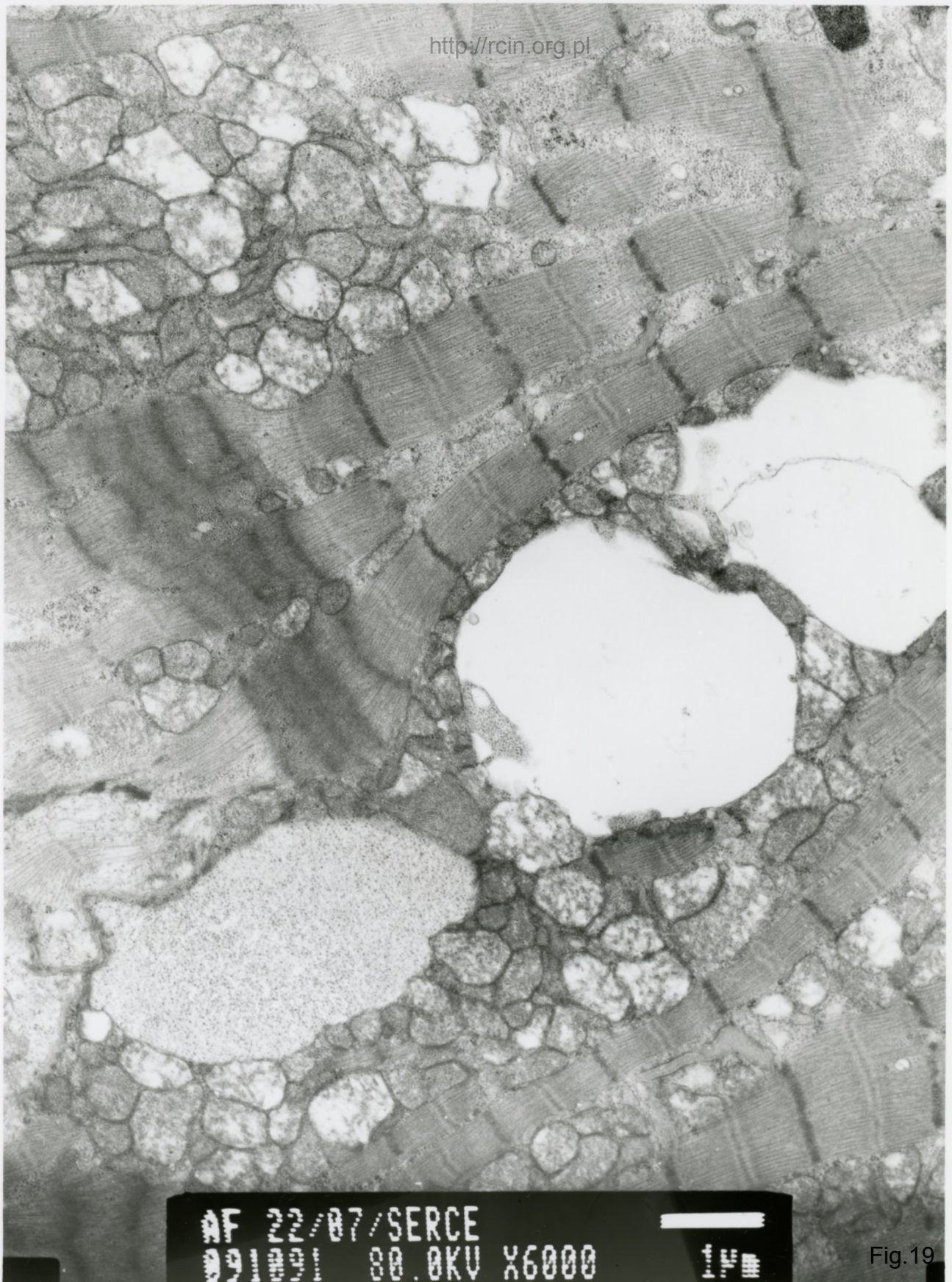

Fig.19

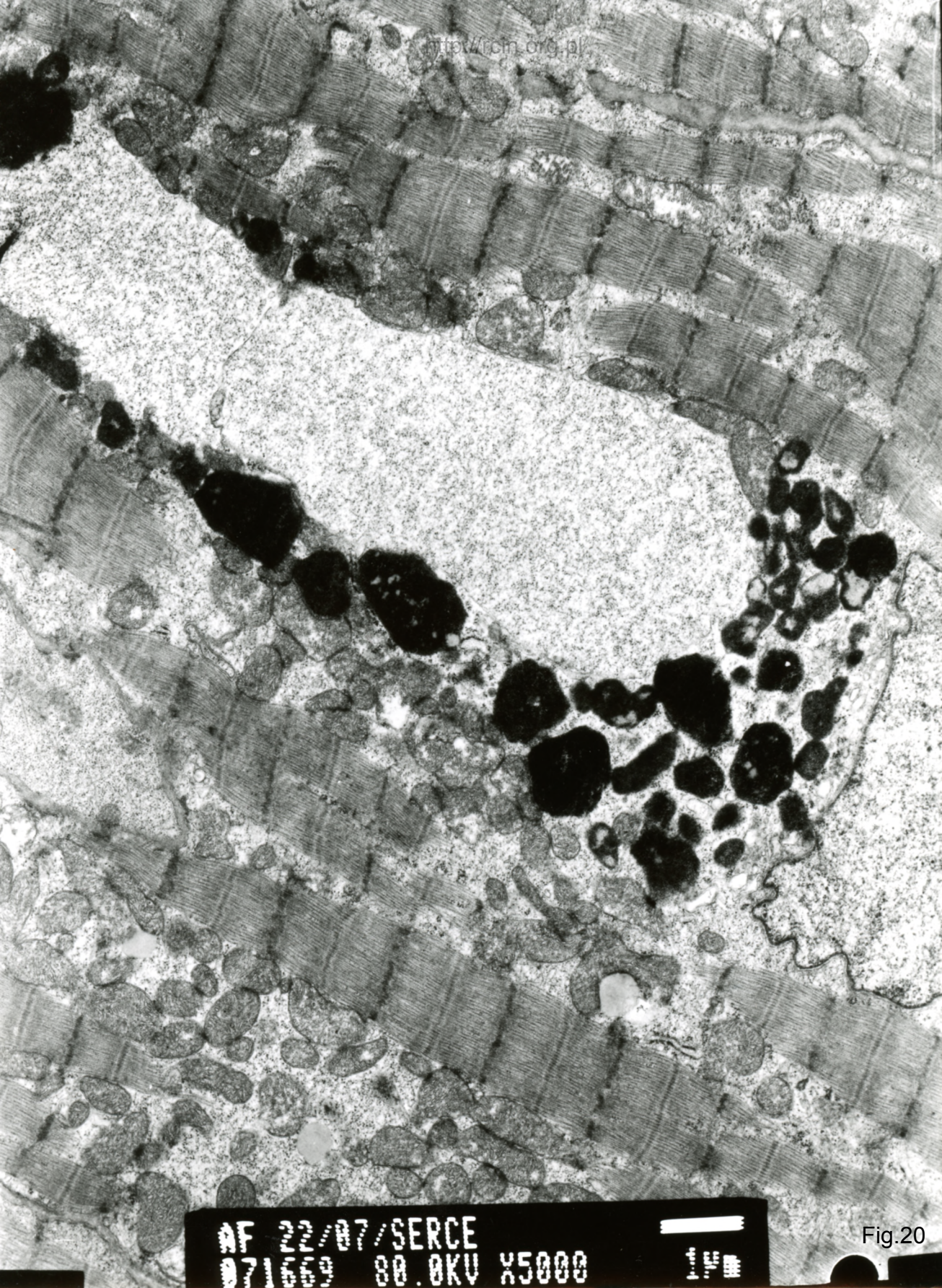

Fig.20

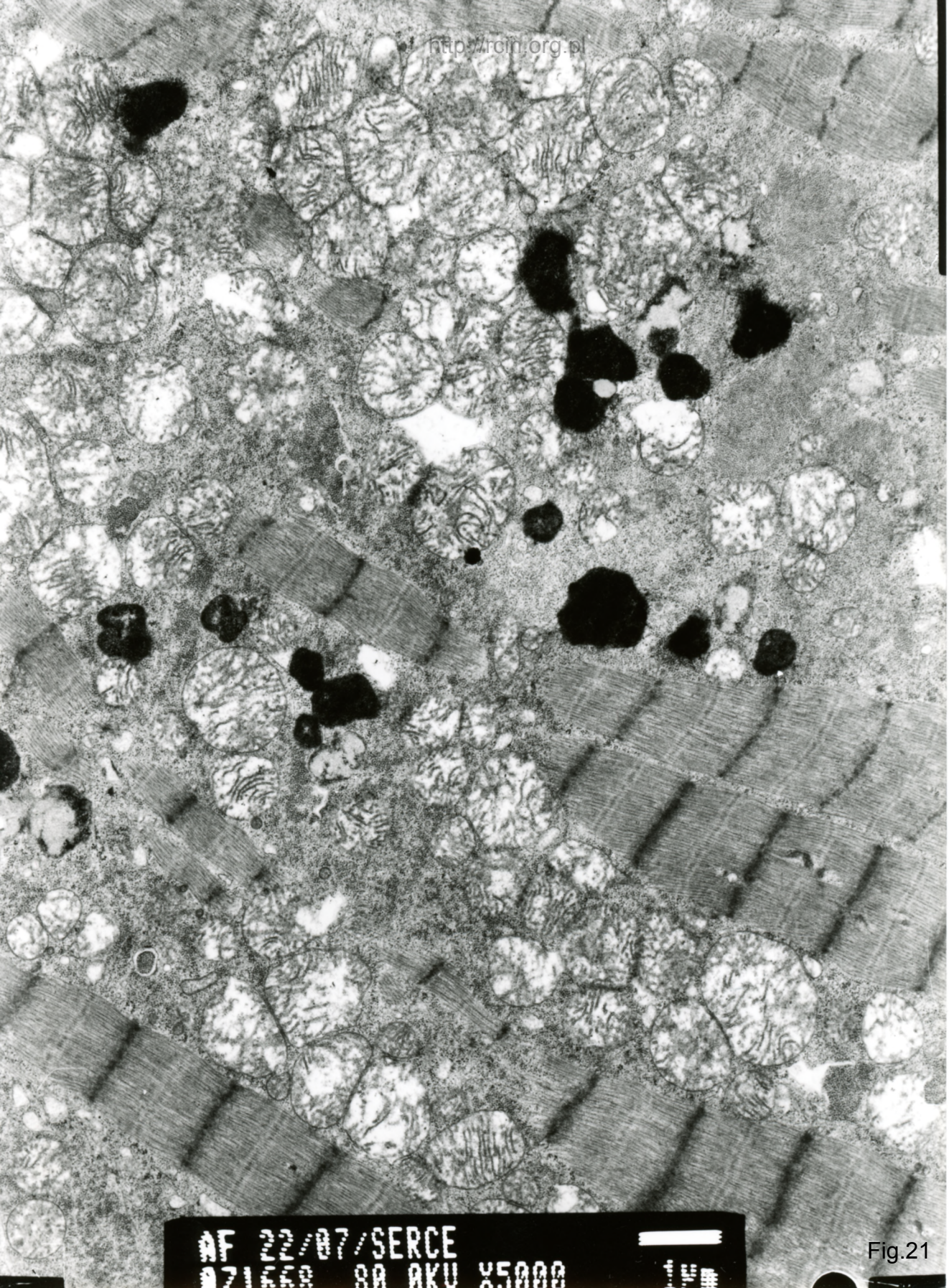

Fig.21

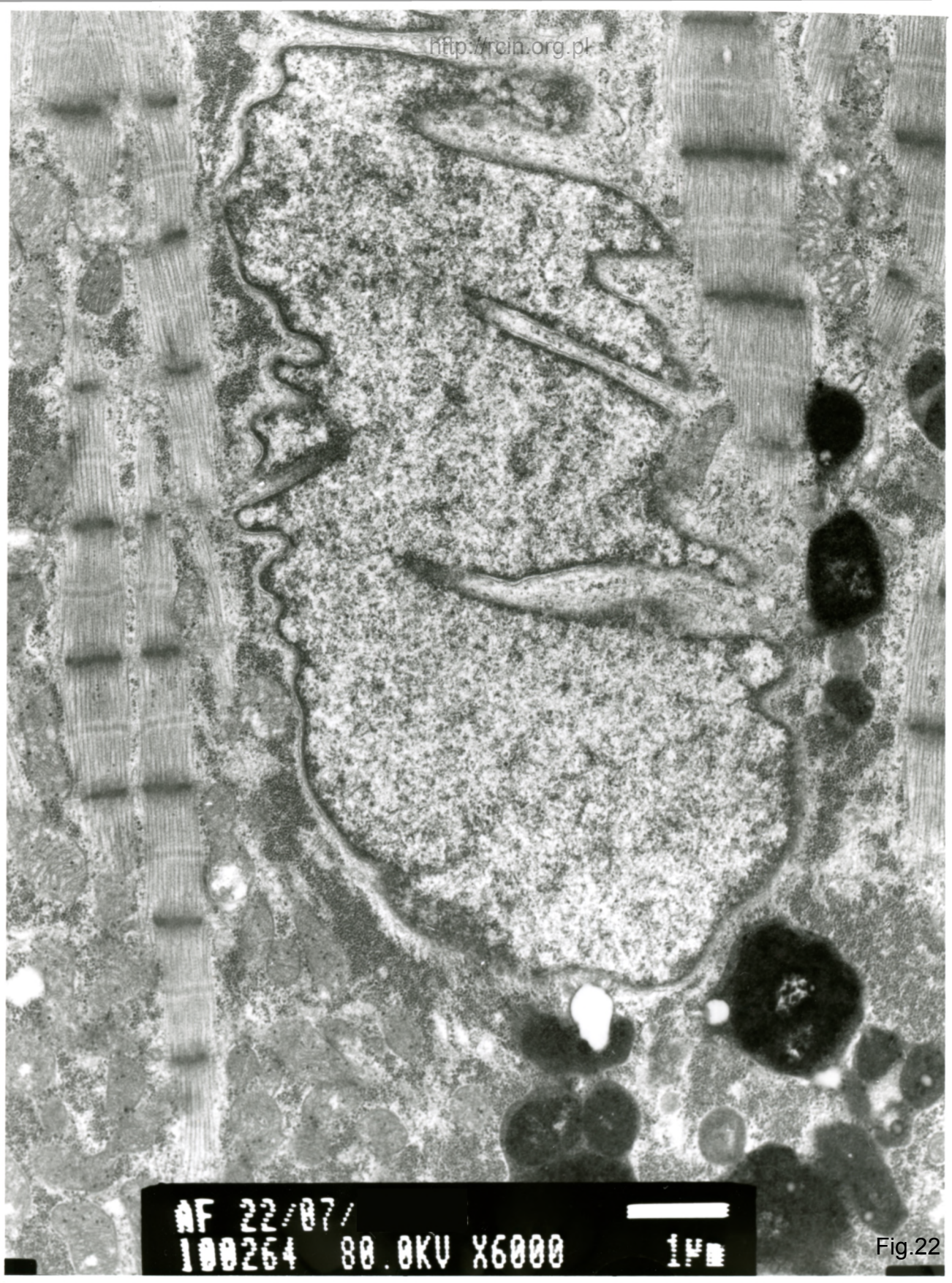

Fig.22

Fig.23

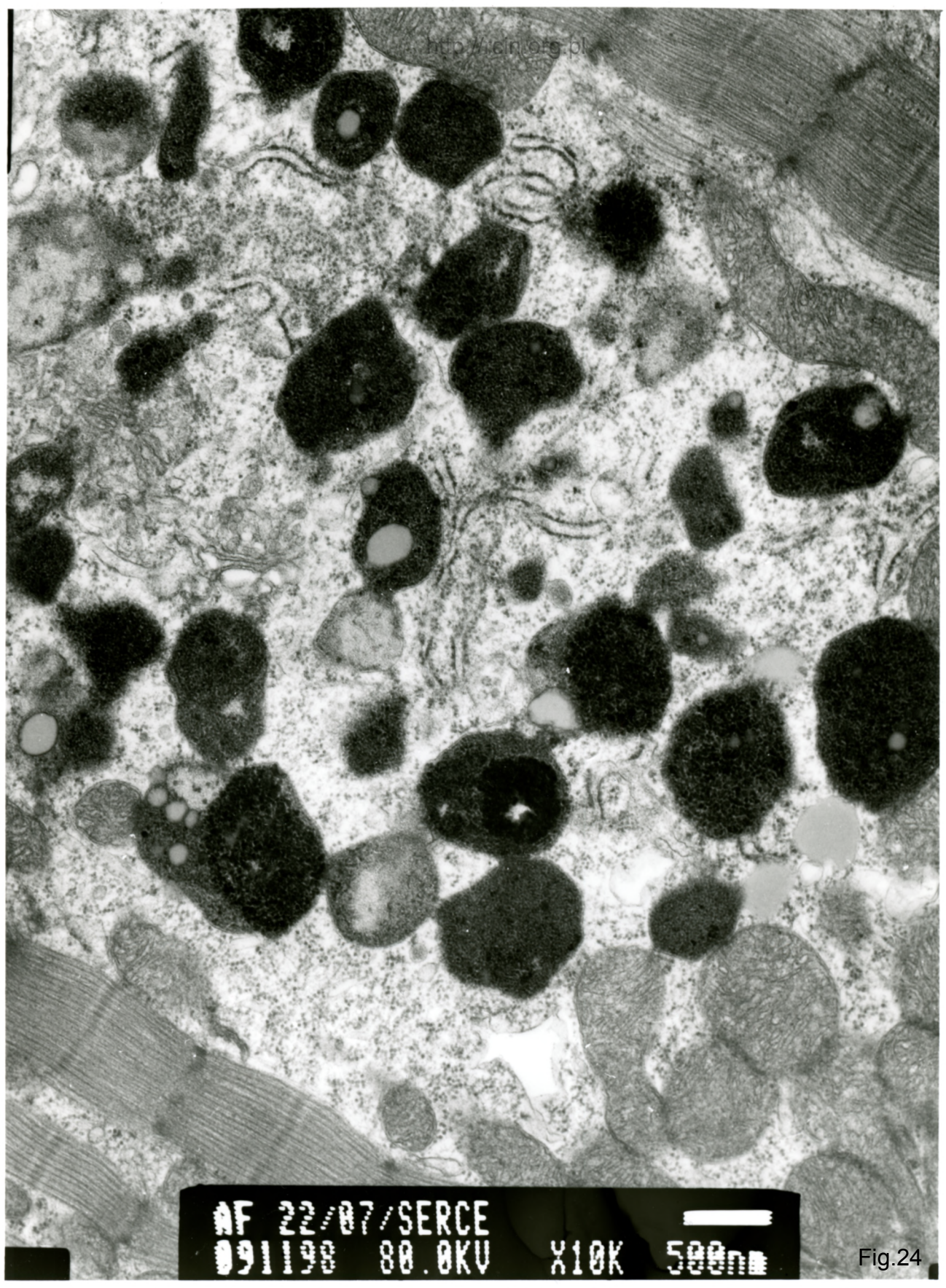

Fig.24

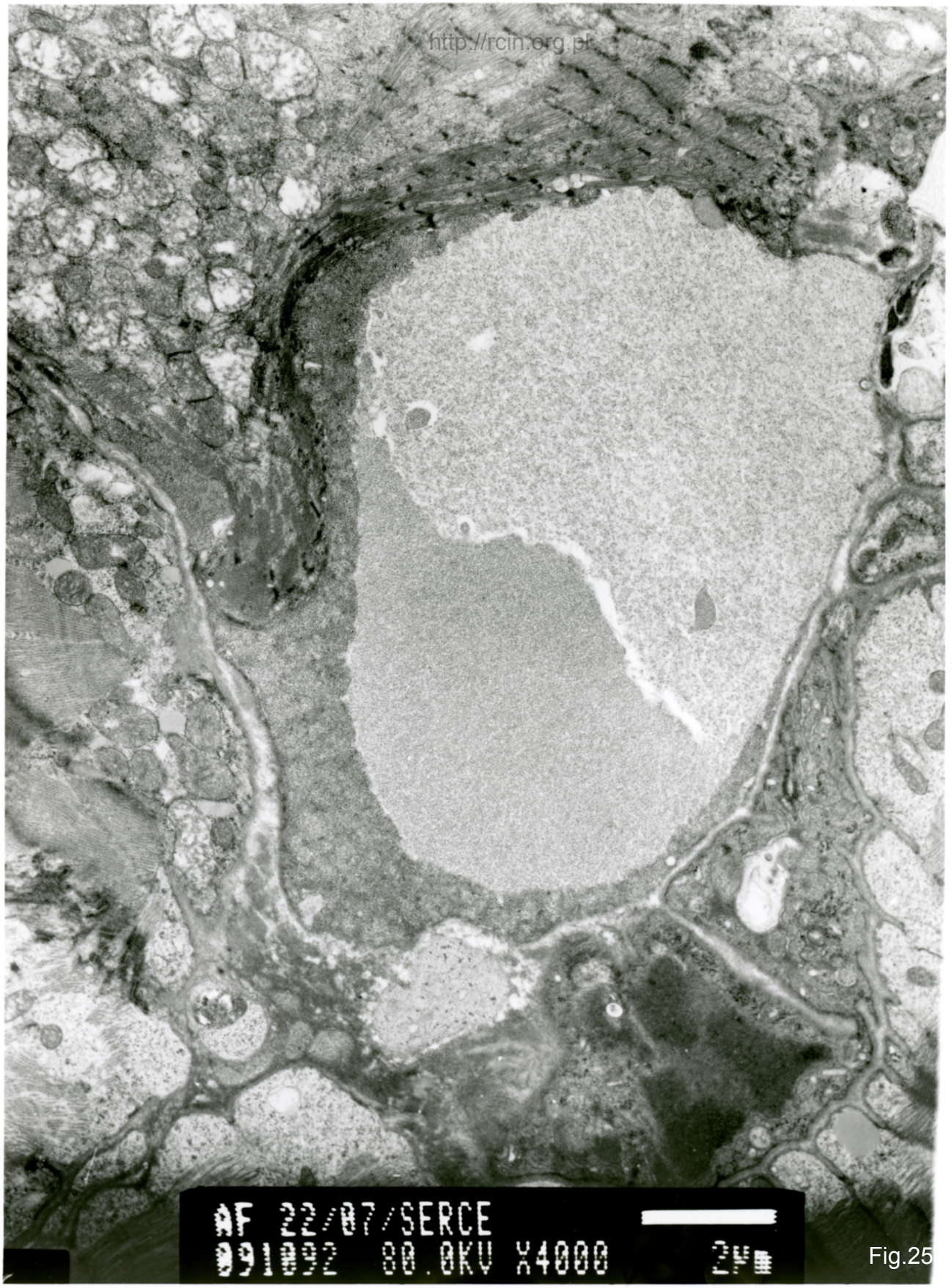

Fig.25

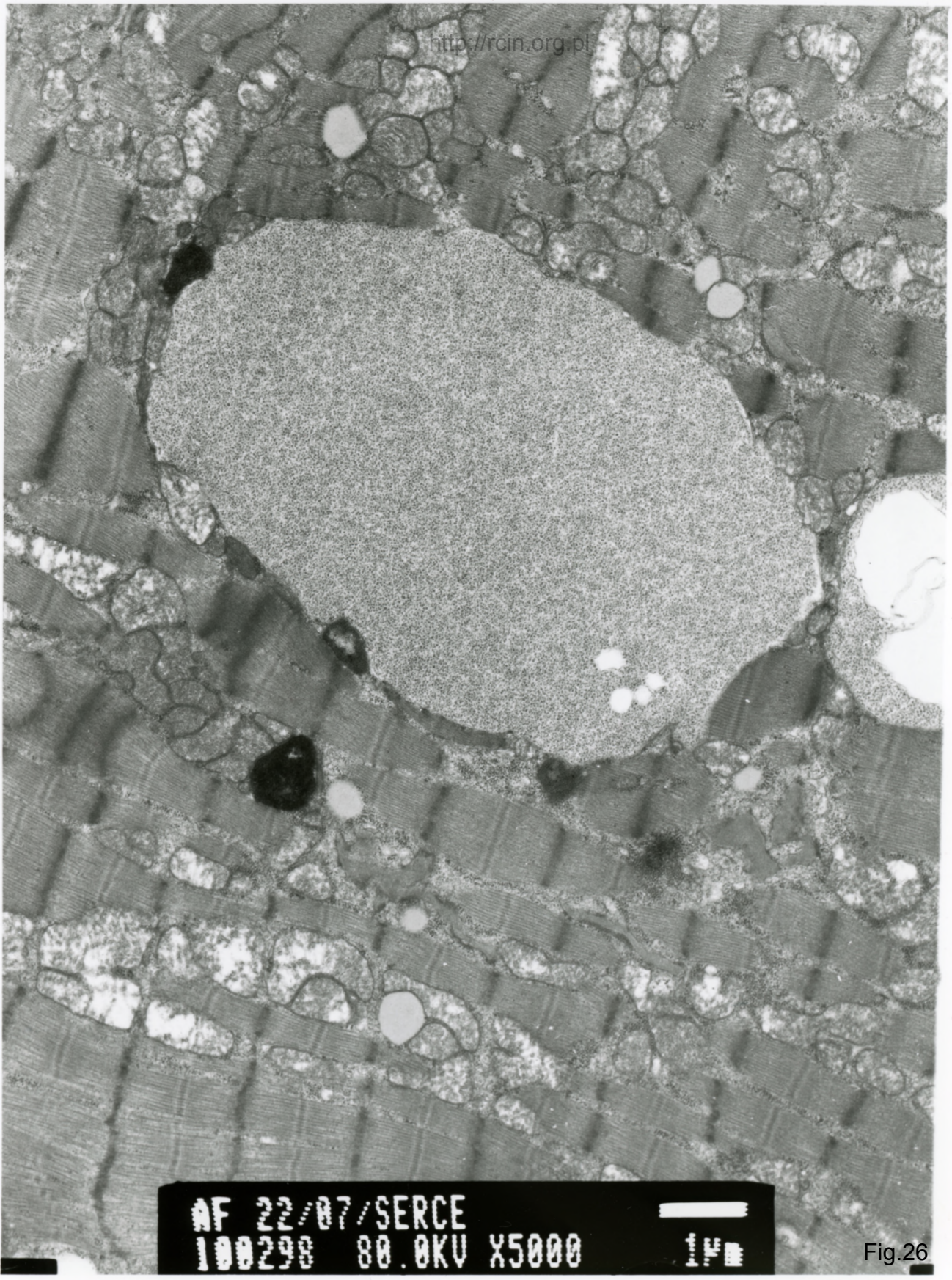

Fig.26



Fig.27

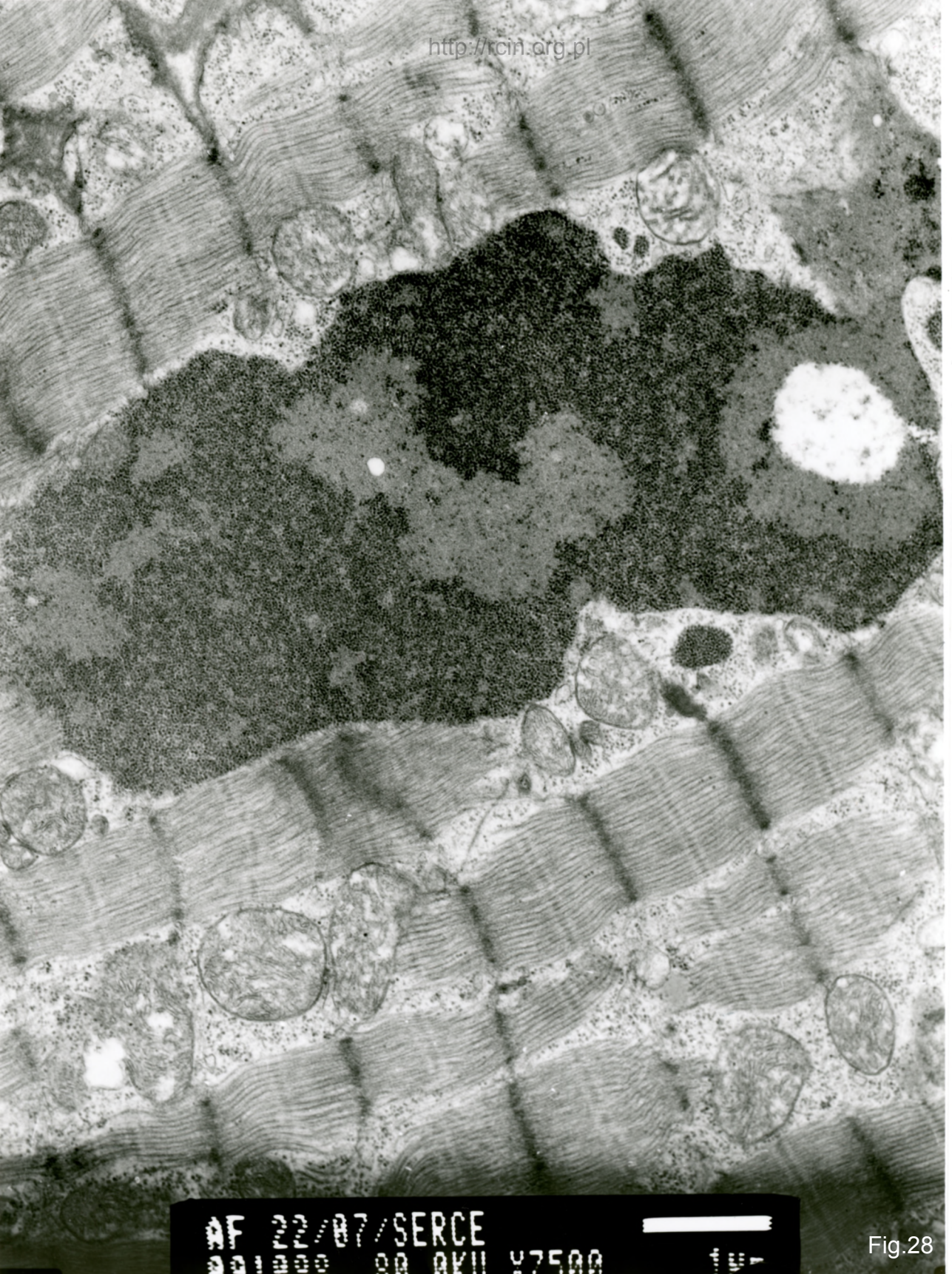

Fig.28

Fig.29

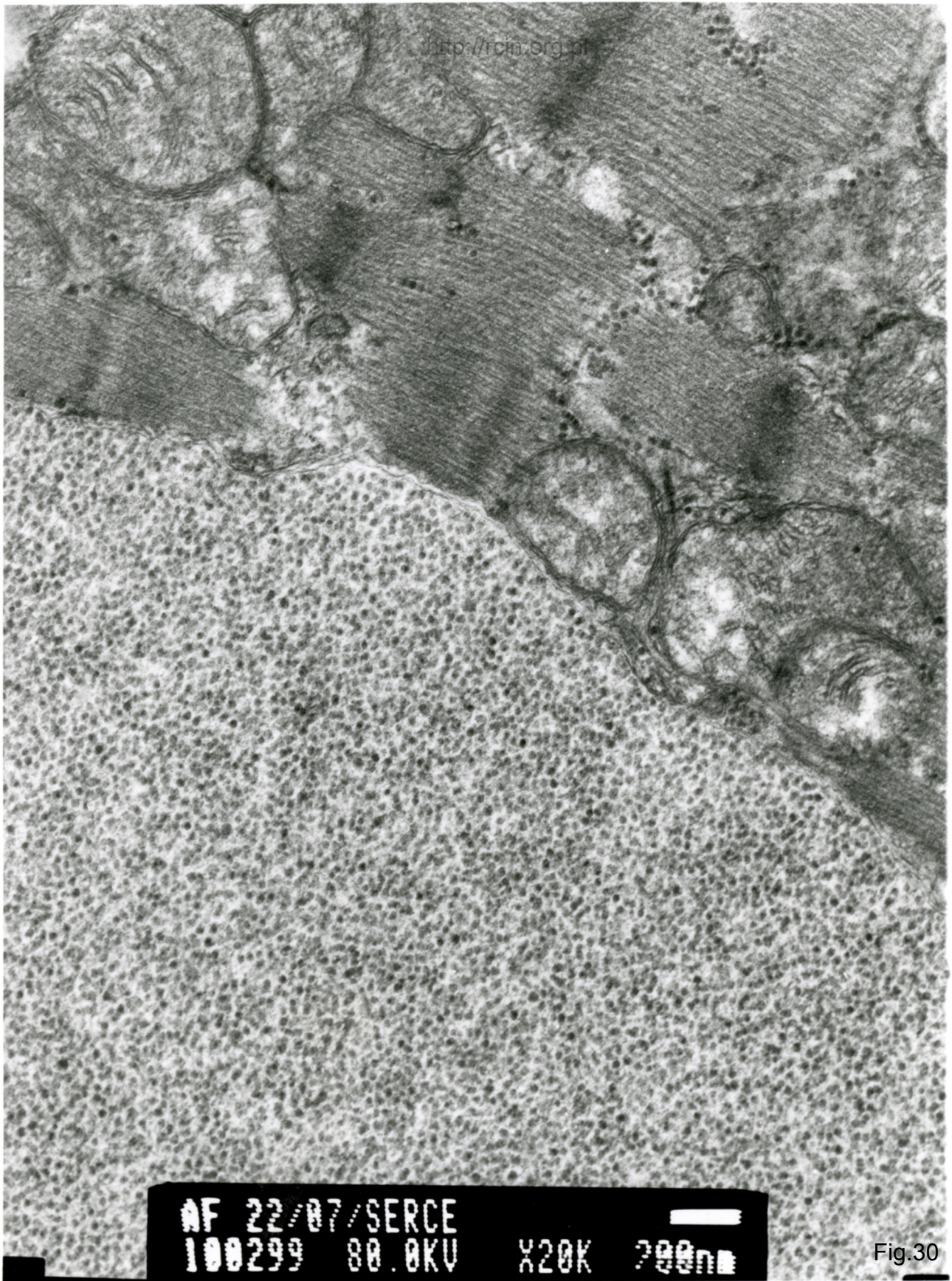

Fig.30

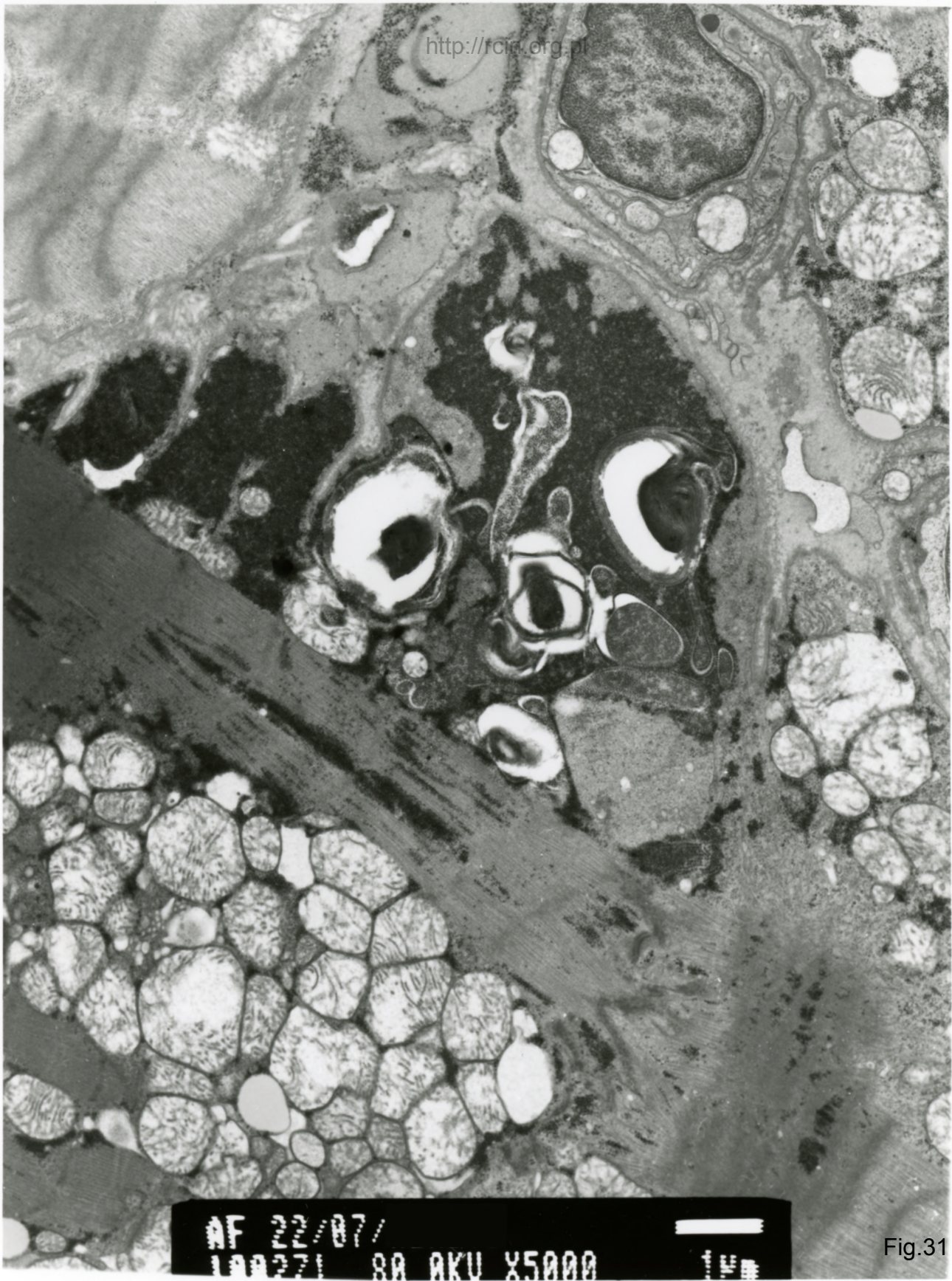

Fig.31

22/07

l. 42

Kardiomiopatia rodzinna, zaburzenia rytmu serca

Analiza ultrastrukturalna wykazała że w części bioptatu architektura kardiomiocytów nie odbiega znacznie od normy (Fig. 1-4). W niektórych komórkach obserwowano jednak, szczególnie w pobliżu jąder kardiomiocytów, dezorganizację sarkomerów i zanik miofibryli (Fig. 5-8). Wiele mitochondriów wykazywało cechy obrzęku, charakteryzowało się jasną macierzą i ubytkiem grzebieni mitochondrialnych (Fig. 9-13). Licznie występowały obłonione wakuole (Fig. 14-19) oraz złogi lipofuscyny (Fig. 20-24). Ogniskowo obserwowano duże nagromadzenie ziaren glikogenu (Fig. 25-30) oraz autofagię (Fig. 31).

Familial cardiomyopathy, arrhythmia

Ultrastructural analysis revealed focally unchanged cardiomyocytes architecture (Figs. 1-4). However, disorganization of sarcomeres and atrophy of myofibrils was observed in some cells, especially in the vicinity of cardiomyocytes nuclei (Figs. 5-8). Many mitochondria were swollen and characterized by a bright mitochondrial matrix and loss of cristae (Figs. 9-13). Vacuole-like structures (Figs. 14-19) and lipofuscin deposits (Figs. 20-24) were abundant. Focally, large accumulation of glycogen granules (Fig. 25-30) and autophagy (Fig. 31) were observed.